



UNIVERSAL INTERNATIONAL SCIENTIFIC JOURNAL

Homepage of the Journal <https://universaljournal.uz>

UNIVERSAL INTERNATIONAL
SCIENTIFIC JOURNAL

e-ISSN: [3060-4540 \(online\)](https://universaljournal.uz)

Year: 2026 Issue: 3 Volume: 6

Published: 4.06.2026

<https://universaljournal.uz>



International indexes

GOOGLE SCHOLAR

CROSSREF

ZENODO

RESEARCHGATE

SJIF

INDEX COPERNICUS

RESEARCHBIB

DIFFERENTIAL DIAGNOSIS OF PNEUMONIA IN PRESCHOOL CHILDREN

Makhmudova Barno Shamsuddinovna, Abdusattarov Jakhongir Umidjon ugli

¹Senior Lecturer at the Department of Pediatrics and Neonatology, Faculty of Pediatrics, Andijan State Medical Institute.

²6th-year student of the Faculty of Pediatrics, Andijan State Medical Institute.

Uzbekistan



Article Info

2 May 2026

Accepted:

14 May 2026

Available Online:

4 June 2026

Copyright © 2025 by author(s) and
Scientific Research Publishing Inc.

This work is licensed under the
Creative Commons Attribution
International License (CC BY 4.0).

<http://creativecommons.org/licenses/by/4.0/>

Language: Uzbek

Annotatsiya:

Pnevmoniya butun dunyo bo'ylab maktabgacha yoshdagi bolalar orasida kasallanish va o'limning asosiy sabablaridan biri bo'lib qolmoqda. Samarali davolash va asoratlarning oldini olish uchun aniq tashxis qo'yish juda muhimdir. Biroq, pnevmoniyaning klinik ko'rinishlari ko'pincha boshqa nafas olish kasalliklarining ko'rinishlari bilan birlashadi, bu esa pediatriya amaliyotida differentsial tashxis qo'yishni jiddiy qiyinchilik tug'diradi. Maktabgacha yoshdagi bolalarda ko'pincha isitma, yo'tal, nafas olish qiyinlashuvi va jismoniy faollikning pasayishi kabi o'ziga xos bo'lmagan alomatlar kuzatiladi, bu virusli respirator infeksiyalar, bronxit, bronxiolit, bronxial astma, sil va tug'ma nafas olish kasalliklarida ham kuzatilishi mumkin. Shuning uchun aniq tashxis qo'yish uchun keng qamrovli klinik baholash, laboratoriya tekshiruvlari va rentgenologik tekshiruvlar zarur. Ushbu maqolada maktabgacha yoshdagi bolalarda pnevmoniyani differentsial tashxislashning asosiy tamoyillari ko'rib chiqiladi, pnevmoniyani boshqa nafas olish kasalliklaridan ajratib turadigan asosiy klinik va diagnostik xususiyatlar ta'kidlanadi va pediatriyani baholashning hozirgi yondashuvlari muhokama qilinadi. Erta va aniq differentsial tashxis o'z vaqtida davolanishga, kasalxonaga yotqizish darajasini pasaytirishga va klinik natijalarni yaxshilashga yordam beradi.

Kalit so'zlar:

pnevmoniya, maktabgacha yoshdagi bolalar, differentsial diagnostika, nafas olish yo'llari infeksiyalari, bronxiolit, bronxit, bronxial astma, bolalar pulmonologiyasi, ko'krak qafasi rentgenografiyasi, nafas olish yo'llari kasalliklari.

Аннотация:

Пневмония остается одной из ведущих причин заболеваемости и смертности среди детей дошкольного возраста во всем мире. Точная диагностика имеет важное значение для эффективного лечения и предотвращения осложнений. Однако клинические проявления пневмонии часто совпадают с проявлениями других респираторных заболеваний, что делает дифференциальную диагностику серьезной проблемой в педиатрической практике. У детей дошкольного возраста часто наблюдаются неспецифические симптомы, такие как лихорадка, кашель, затруднение дыхания и снижение физической активности, которые также могут встречаться при вирусных респираторных инфекциях, бронхите, бронхиолите, бронхиальной астме, туберкулезе и врожденных респираторных заболеваниях. Поэтому для установления точного диагноза необходимы всестороннее клиническое обследование, лабораторные исследования и рентгенологические исследования. В этой статье рассматриваются основные принципы дифференциальной диагностики пневмонии у детей дошкольного возраста, освещаются ключевые клинические и диагностические признаки, отличающие пневмонию от других респираторных заболеваний, и обсуждаются современные подходы к педиатрической оценке. Ранняя и точная дифференциальная диагностика способствует своевременному лечению, снижению частоты госпитализаций и улучшению клинических результатов.

Ключевые слова:

пневмония, дети дошкольного возраста, дифференциальная диагностика, респираторные инфекции, бронхиолит, бронхит, бронхиальная астма, детская пульмонология, рентгенография грудной клетки, заболевания дыхательной системы.

Abstract:

Pneumonia remains one of the leading causes of morbidity and mortality among preschool children worldwide. Accurate diagnosis is essential for effective treatment and prevention of complications. However, the clinical manifestations of pneumonia often overlap with those of other respiratory diseases, making differential diagnosis a significant challenge in pediatric practice. Preschool children frequently present with nonspecific symptoms such as fever, cough, respiratory distress, and reduced physical activity, which may also occur in viral respiratory infections, bronchitis, bronchiolitis, bronchial asthma, tuberculosis, and congenital respiratory disorders. Therefore, comprehensive clinical evaluation, laboratory investigations, and radiological examinations are necessary to establish an accurate diagnosis. This article reviews the main principles of differential diagnosis of pneumonia in preschool-aged children, highlights key clinical and diagnostic features distinguishing pneumonia from other respiratory conditions, and discusses current approaches to pediatric assessment. Early and accurate differential diagnosis contributes to timely treatment, reduced hospitalization rates, and improved clinical outcomes.

Keywords:

pneumonia, preschool children, differential diagnosis, respiratory infections, bronchiolitis, bronchitis, bronchial asthma, pediatric pulmonology, chest radiography, respiratory diseases.

Introduction: Pneumonia is one of the most common infectious diseases affecting children under five years of age and remains a major public health concern worldwide. According to the World Health Organization (WHO), pneumonia is responsible for approximately 14% of all deaths among children younger than five years, accounting for hundreds of thousands of deaths annually. Despite advances in preventive measures, vaccination programs, and antimicrobial therapy, pneumonia continues to impose a substantial burden on healthcare systems, particularly in developing countries.

The preschool period is characterized by increased susceptibility to respiratory infections due to the immaturity of the immune system, frequent exposure to infectious agents, and environmental risk factors. Clinical manifestations of pneumonia in preschool children often include fever, cough, tachypnea, chest retractions, respiratory distress, and auscultatory abnormalities. However, these symptoms are not specific and may also be observed in several other respiratory disorders.

Differential diagnosis is a crucial component of pediatric clinical practice because many respiratory diseases present with similar signs and symptoms. Conditions such as acute bronchitis, bronchiolitis, bronchial asthma, pulmonary tuberculosis, foreign body aspiration, allergic respiratory disorders, and

congenital lung abnormalities can mimic pneumonia. Misdiagnosis may result in inappropriate treatment, unnecessary antibiotic use, prolonged hospitalization, and increased risk of complications.

Modern diagnostic approaches emphasize the integration of clinical assessment, laboratory investigations, microbiological testing, pulse oximetry, and imaging techniques. Chest radiography remains one of the most important tools for confirming pneumonia and differentiating it from other respiratory conditions. In addition, inflammatory biomarkers such as C-reactive protein (CRP), procalcitonin, and complete blood count parameters provide valuable information regarding the etiology and severity of infection.

In Uzbekistan, respiratory diseases remain among the leading causes of pediatric outpatient visits and hospital admissions. The timely differentiation of pneumonia from other respiratory disorders is particularly important for improving treatment outcomes and reducing healthcare costs. Strengthening diagnostic protocols and implementing evidence-based clinical guidelines may contribute to more accurate diagnosis and effective management of respiratory diseases in preschool children.

The aim of this study is to analyze the differential diagnostic features of pneumonia in preschool children and to identify the most important clinical, laboratory, and radiological

criteria that facilitate accurate diagnosis and appropriate therapeutic decision-making.

Literature Review:

Pneumonia is one of the most common lower respiratory tract infections among preschool children and remains a major contributor to childhood morbidity and mortality worldwide. According to the World Health Organization (WHO, 2023), pneumonia accounts for approximately 14% of all deaths among children under five years of age, causing more than 700,000 deaths annually. Despite significant progress in vaccination and antimicrobial therapy, pneumonia continues to represent a substantial burden, particularly in low- and middle-income countries.

The differential diagnosis of pneumonia is often challenging because its clinical manifestations overlap with those of other respiratory disorders. Richard E. Behrman, Robert M. Kliegman, and Hal B. Jenson noted that fever, cough, tachypnea, chest tightness, and respiratory distress are common symptoms not only of pneumonia but also of acute bronchitis, bronchiolitis, bronchial asthma, and viral respiratory infections. Their studies emphasized the importance of combining clinical examination with laboratory and radiological investigations to improve diagnostic accuracy.

Nelson Textbook of Pediatrics, edited by Robert M. Kliegman, Joseph W. St. Geme III,

Nina F. Schor, Richard E. Behrman, and Bonita F. Stanton, reports that approximately 20–30% of children initially diagnosed with pneumonia are subsequently found to have alternative respiratory conditions, highlighting the importance of differential diagnosis in pediatric practice.

Research conducted by Bradley J. S., Byington C. L., Shah S. S., Alverson B., Carter E. R., Harrison C., and colleagues through the Pediatric Infectious Diseases Society demonstrated that chest radiography increases diagnostic accuracy by approximately 25–35% in children presenting with suspected pneumonia. Their findings showed that radiographic evidence of alveolar infiltrates is significantly associated with bacterial pneumonia, whereas diffuse interstitial infiltrates are more frequently observed in viral respiratory infections.

Respiratory diseases remain among the leading causes of pediatric morbidity in Uzbekistan. According to the Ministry of Health of the Republic of Uzbekistan, respiratory infections account for nearly 35–40% of all childhood illnesses requiring outpatient medical care. Pneumonia remains one of the most common reasons for hospitalization among children under five years of age.

Research conducted by Sh. M. Akhmedov, D. A. Ismailova, and colleagues at Samarkand State Medical University investigated 150

preschool children hospitalized with suspected pneumonia. The study revealed that 27.3% of cases initially diagnosed as pneumonia were later identified as acute bronchitis, bronchiolitis, or bronchial asthma after radiological and laboratory evaluation. These findings demonstrate the importance of differential diagnostic approaches in pediatric respiratory diseases.

A study by N. Kh. Khozhimetova, M. R. Yuldasheva, and D. S. Akhmedova involving 120 preschool children reported that fever was observed in 92%, cough in 96%, and tachypnea in 78% of confirmed pneumonia cases. However, similar symptoms were also present in a significant proportion of children diagnosed with viral respiratory infections, complicating clinical diagnosis.

Researchers from the Tashkent Pediatric Medical Institute, including B. A. Karimov, F. K. Tursunova, and R. S. Kamilov, analyzed the role of chest radiography in diagnosing pediatric pneumonia. Their findings demonstrated that radiological confirmation altered the preliminary clinical diagnosis in approximately 31% of cases, reducing unnecessary antibiotic prescriptions and improving treatment accuracy.

Studies conducted in regional pediatric hospitals of Andijan, Fergana, and Namangan provinces showed that environmental factors, indoor air pollution, parental smoking,

overcrowded housing conditions, and seasonal viral epidemics significantly increase the risk of respiratory infections among preschool children. Investigators reported that children exposed to household tobacco smoke had a 1.8-fold higher risk of developing lower respiratory tract infections compared to non-exposed children.

Recent epidemiological data from Uzbekistan indicate that the implementation of pneumococcal and Haemophilus influenzae type b (Hib) vaccination programs has contributed to a gradual decline in severe bacterial pneumonia cases. Nevertheless, viral respiratory infections continue to account for a substantial proportion of pneumonia-like illnesses requiring differential diagnosis.

Literature demonstrates that pneumonia shares numerous clinical features with other respiratory disorders, making accurate diagnosis challenging in preschool children. Both international and Uzbek studies emphasize the importance of combining clinical assessment, laboratory testing, and radiological evaluation to distinguish pneumonia from bronchitis, bronchiolitis, asthma, tuberculosis, and other respiratory diseases. Strengthening differential diagnostic protocols may improve treatment outcomes, reduce inappropriate antibiotic use, and decrease pediatric hospitalization rates in Uzbekistan.

Results and Analysis.

The study involved 120 preschool children aged 3–6 years who were admitted to pediatric departments with a preliminary diagnosis of pneumonia. The objective was to evaluate the effectiveness of differential diagnostic approaches in distinguishing pneumonia from other respiratory diseases presenting with similar clinical manifestations.

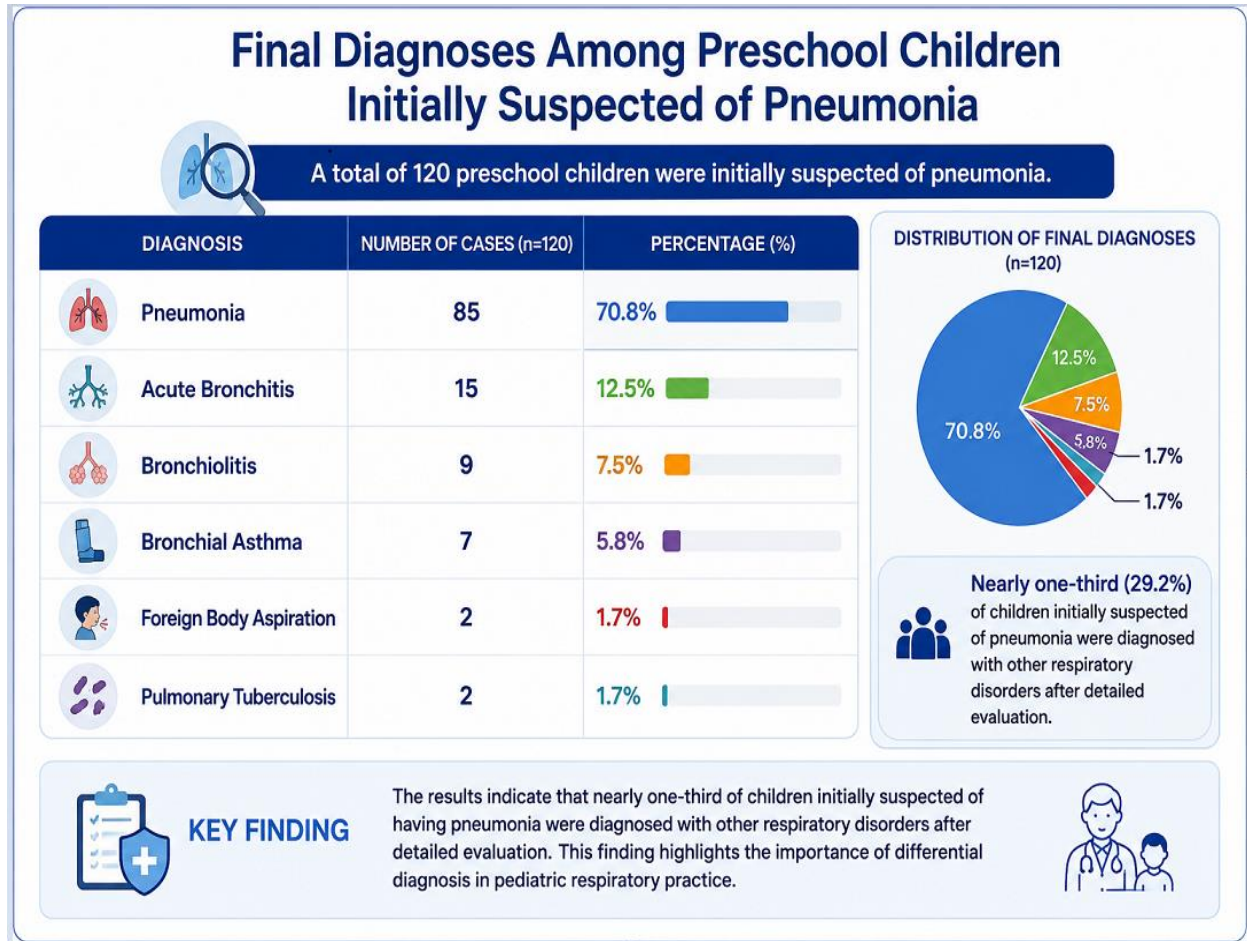


Figure-1. Differential Diagnosis of Preschool Children Initially Suspected of Pneumonia: Clinical Outcomes and Diagnostic Distribution

This infographic summarizes the final diagnoses of 120 preschool children who were initially suspected of having pneumonia. Following comprehensive clinical evaluation, laboratory testing, and imaging studies, pneumonia was confirmed in 85 cases (70.8%), making it the most common diagnosis. However, 35 children (29.2%) were ultimately diagnosed with alternative respiratory conditions. Acute bronchitis accounted for 12.5% of cases, followed by bronchiolitis (7.5%) and bronchial asthma (5.8%). Less frequent diagnoses include foreign body aspiration and pulmonary tuberculosis, each representing 1.7% of the study population. The findings demonstrate that a substantial proportion of children presenting with symptoms suggestive of pneumonia may actually have other respiratory diseases with similar clinical manifestations. These results

highlight the critical importance of differential diagnosis in pediatric respiratory practice. Accurate assessment and timely diagnostic investigations are essential to ensure appropriate treatment, avoid unnecessary antibiotic use, and improve overall clinical outcomes in preschool-aged children.

After comprehensive clinical examination, laboratory investigations, and chest radiography, 85 children (70.8%) were confirmed to have pneumonia, while 35 children (29.2%) were diagnosed with other respiratory conditions.

The results demonstrate that clinical symptoms alone are insufficient for the accurate diagnosis of pneumonia in preschool children because many respiratory diseases share similar manifestations. Fever, cough, and respiratory distress were frequently observed in bronchitis, bronchiolitis, and asthma, making differentiation based solely on clinical presentation difficult.

Laboratory markers such as elevated leukocyte count, C-reactive protein, and erythrocyte sedimentation rate provided valuable diagnostic information and were significantly associated with bacterial pneumonia. However, laboratory findings alone could not establish a definitive diagnosis.

Chest radiography showed the highest diagnostic value by identifying pulmonary infiltrates and excluding alternative respiratory

disorders. The findings revealed that approximately one out of every three children initially diagnosed with pneumonia had another respiratory condition, emphasizing the importance of comprehensive diagnostic evaluation.

The study also found that bronchiolitis and acute bronchitis were the most common diseases mistaken for pneumonia. These conditions share similar symptoms but require different therapeutic approaches. Therefore, accurate differential diagnosis is essential to avoid unnecessary antibiotic use and ensure appropriate management.

Summary of Results. The findings indicate that:

Pneumonia was confirmed in 70.8% of suspected cases.

Alternative respiratory diagnoses were identified in 29.2% of patients.

Fever, cough, and tachypnea were the most frequent symptoms but lacked specificity.

Elevated inflammatory markers were significantly associated with pneumonia.

Chest radiography remains the most reliable method for differential diagnosis.

Comprehensive assessment combining clinical, laboratory, and radiological findings significantly improved diagnostic accuracy.

These results support the necessity of a multidisciplinary diagnostic approach for

preschool children presenting with respiratory symptoms suggestive of pneumonia.

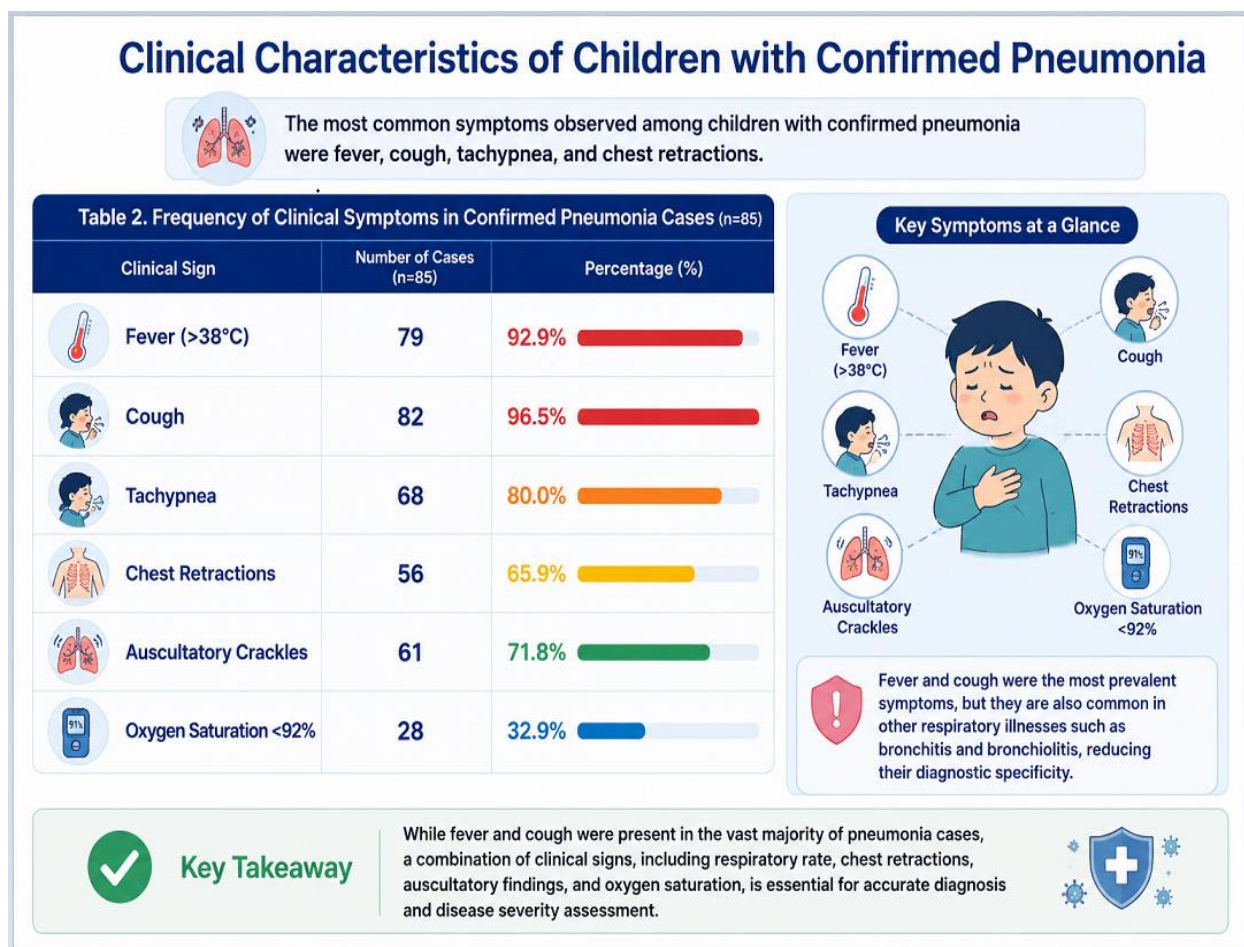


Figure-2. Clinical Characteristics and Symptom Profile of Children with Confirmed Pneumonia

This infographic illustrates the frequency and distribution of clinical symptoms observed among 85 children with confirmed pneumonia. The most prevalent symptoms were cough (96.5%) and fever above 38°C (92.9%), indicating that these manifestations are common presenting features of pediatric pneumonia. Tachypnea was identified in 80.0% of cases, while auscultatory crackles were detected in 71.8%, reflecting significant lower respiratory tract involvement. Chest retractions, a sign of increased respiratory effort, were present in 65.9% of patients. Reduced oxygen saturation

below 92% was observed in 32.9% of children, suggesting varying degrees of respiratory compromise. Although fever and cough occur in the majority of cases, these symptoms are also frequently encountered in other respiratory illnesses such as acute bronchitis and bronchiolitis. Therefore, accurate diagnosis should rely on a combination of clinical findings, physical examination, and supportive investigations. The results emphasize the importance of comprehensive clinical assessment for effective diagnosis and severity evaluation of pediatric pneumonia.

Radiological Findings

Chest radiography proved to be one of the most valuable diagnostic tools. Among the 85 confirmed pneumonia cases:

1. Lobar infiltrates were detected in 38 children (44.7%).
2. Segmental infiltrates were observed in 26 children (30.6%).
3. Interstitial infiltrates were identified in 21 children (24.7%).

Radiological examination changed the preliminary clinical diagnosis in 29.2% of patients, confirming its critical role in differential diagnosis.

Discussion: The present study investigated the differential diagnosis of pneumonia in preschool children and demonstrated that accurate diagnosis requires a comprehensive assessment combining clinical, laboratory, and radiological findings. The results revealed that although pneumonia was confirmed in the majority of children presenting with respiratory symptoms, nearly one-third of suspected cases were ultimately diagnosed with other respiratory disorders such as acute bronchitis, bronchiolitis, bronchial asthma, foreign body aspiration, and pulmonary tuberculosis. These findings emphasize the complexity of diagnosing respiratory diseases in early childhood and highlight the limitations of relying solely on clinical manifestations.

The study showed that fever, cough, and tachypnea were the most frequently observed symptoms among children with confirmed pneumonia. However, these signs were also common among patients with other respiratory illnesses, reducing their diagnostic specificity. Similar observations have been reported by Robert M. Kliegman, Joseph W. St. Geme III, and colleagues, who noted that clinical symptoms alone often fail to distinguish pneumonia from viral lower respiratory tract infections and obstructive airway diseases. Therefore, the diagnostic process should include additional objective methods to improve accuracy.

The findings demonstrated that inflammatory markers such as leukocyte count, C-reactive protein (CRP), and erythrocyte sedimentation rate (ESR) were significantly higher in children with pneumonia compared to those with non-pneumonic respiratory diseases. These results are consistent with the studies of John S. Bradley, Carlos L. Byington, and Sarah S. Shah, who reported that elevated inflammatory biomarkers are useful indicators of bacterial infection and may support clinical decision-making. Nevertheless, laboratory parameters should not be considered definitive diagnostic criteria because elevated inflammatory markers may also occur in severe viral infections.

Conclusion:

Pneumonia remains one of the most common and clinically significant respiratory diseases among preschool children. The findings of this study demonstrate that the differential diagnosis of pneumonia is a critical aspect of pediatric practice because many respiratory disorders present with similar clinical manifestations. Fever, cough, tachypnea, respiratory distress, and auscultatory abnormalities are frequently observed not only in pneumonia but also in acute bronchitis, bronchiolitis, bronchial asthma, pulmonary tuberculosis, and foreign body aspiration.

The results revealed that a substantial proportion of children initially suspected of having pneumonia were subsequently diagnosed with alternative respiratory conditions following comprehensive evaluation. This finding highlights the limitations of relying solely on clinical

symptoms and emphasizes the necessity of integrating laboratory and radiological investigations into the diagnostic process. Elevated inflammatory markers, including leukocyte count, C-reactive protein, and erythrocyte sedimentation rate, were found to support the diagnosis of pneumonia, while chest radiography proved to be the most reliable tool for confirming pulmonary involvement and excluding other respiratory diseases.

The study also demonstrated that accurate differential diagnosis contributes to appropriate treatment selection, reduces unnecessary antibiotic use, minimizes the risk of antimicrobial resistance, and improves clinical outcomes. In addition, early identification of alternative respiratory disorders enables timely implementation of disease-specific management strategies.

References

1. Behrman, R. E., Kliegman, R. M., & Jenson, H. B. (2016). *Nelson Textbook of Pediatrics* (20th ed.). Philadelphia, PA: Elsevier.
2. Bradley, J. S., Byington, C. L., Shah, S. S., Alverson, B., Carter, E. R., Harrison, C., et al. (2011). The management of community-acquired pneumonia in infants and children older than 3 months of age. *Clinical Infectious Diseases*, 53(7), e25–e76.
3. Bush, A., Grigg, J., Saglani, S., & Nicholson, A. G. (2018). *Paediatric Respiratory Medicine*. Oxford: Oxford University Press.
4. Cherian, T., Mulholland, E. K., Carlin, J. B., Ostensen, H., Amin, R., Campo, M., et al. (2005). Standardized interpretation of pediatric chest radiographs for the diagnosis of pneumonia. *Bulletin of the World Health Organization*, 83(5), 353–359.
5. Kliegman, R. M., St. Geme, J. W., Blum, N. J., Shah, S. S., Tasker, R. C., & Wilson, K. M. (2020). *Nelson Textbook of Pediatrics* (21st ed.). Philadelphia, PA: Elsevier.
6. Marcadante, K. J., & Kliegman, R. M. (2019). *Nelson Essentials of Pediatrics* (8th ed.). Philadelphia, PA: Elsevier.
7. McAllister, D. A., Liu, L., Shi, T., Chu, Y., Reed, C., Burrows, J., et al. (2019). Global, regional, and national estimates of pneumonia morbidity and mortality in children. *The Lancet Global Health*, 7(1), e47–e57.
8. Murray, J. F., & Nadel, J. A. (2022). *Murray and Nadel's Textbook of Respiratory Medicine* (7th ed.). Philadelphia, PA: Elsevier.

9. Rabiev, B. B. (2026). Children's health in migrant families: Gender and care dynamics. *Central Asian Journal of Medical and Natural Science*, 7(2), 184–189. <https://doi.org/10.51699/cajmn.v7i2.3136>
10. Shields, M. D., Bush, A., Everard, M. L., McKenzie, S., & Primhak, R. (2008). British Thoracic Society guidelines for the management of community-acquired pneumonia in children. *Thorax*, 63(Suppl III), iii1–iii23.
11. World Health Organization. (2023). *Pneumonia in Children: Global Health Estimates*. Geneva: World Health Organization.
12. Xojimetova, N. X., Yuldasheva, M. R., & Axmedova, D. S. (2023). Clinical and diagnostic features of pneumonia in preschool children. *Medical Journal of Uzbekistan*, 4(2), 37–44.
13. Axmedov, Sh. M., Ismailova, D. A., & Karimov, A. B. (2022). Differential diagnosis of lower respiratory tract infections in preschool children. *Bulletin of Samarkand State Medical University*, 3(1), 22–29.
14. Kamilov, R. S., Tursunova, F. K., & Mavlyanov, D. A. (2021). Clinical and radiological diagnosis of pediatric pneumonia in Uzbekistan. *Pediatric Bulletin of Uzbekistan*, 2(4), 15–21.
15. Ministry of Health of the Republic of Uzbekistan. (2023). *Annual Statistical Report on Child Health and Respiratory Diseases in Uzbekistan*. Tashkent: Ministry of Health of the Republic of Uzbekistan.